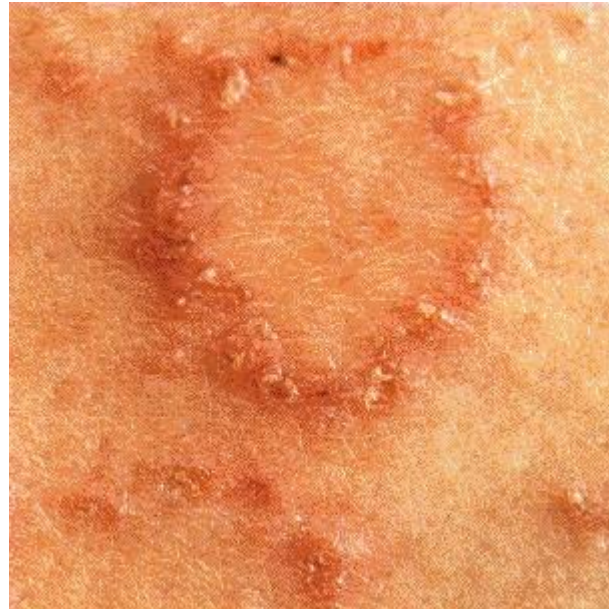

Case 3

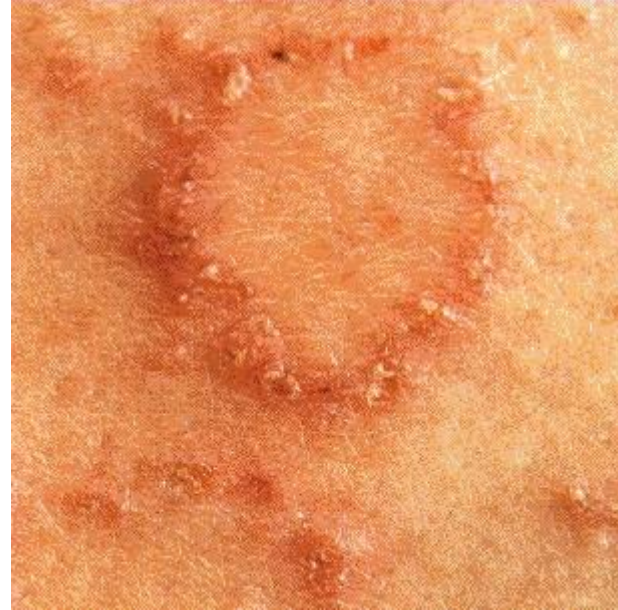- Michael comes to you with round itchy red patches on his arms.

- Diagnosis?



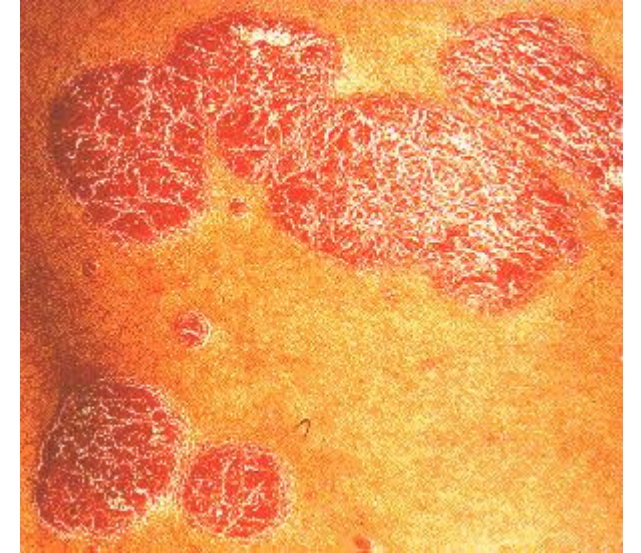
Discoid eczema

- Round/oval itchy patches
- Limbs/extensor surfaces
- More resistant to therapy versus atopic eczema



- How would you differentiate discoid eczema from tinea?
- How would you differentiate discoid eczema from psoriasis?

- Discoid eczema Vs Psoriasis
 - Lighter in colour and lack scale
 - Auspitz's sign negative



- Discoid eczema vs tinea
 - Tinea does not respond/gets worse with topical corticosteroids
 - Scrapings taken if any doubt

